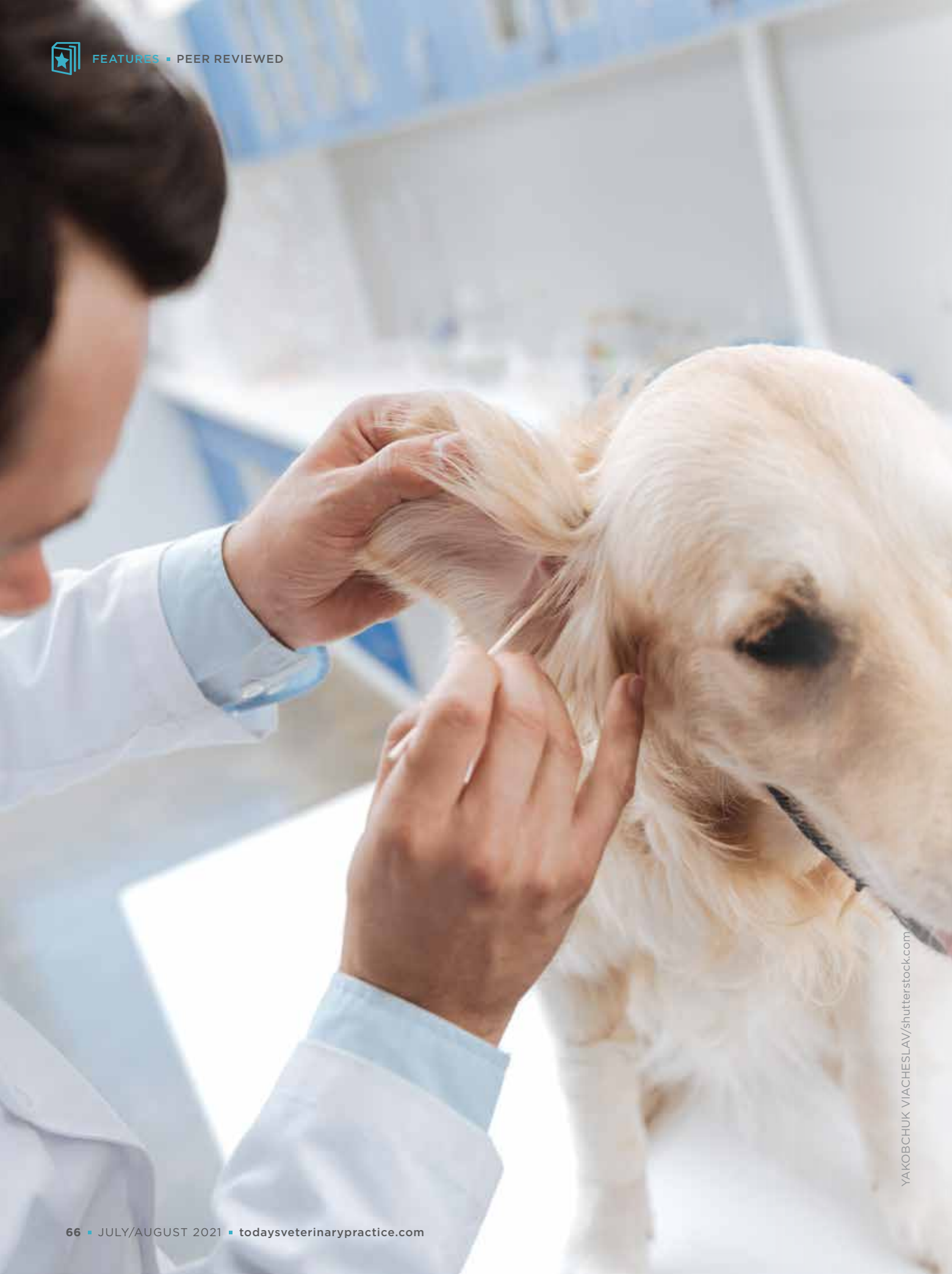



YAKOBCHUK VIACHESLAV/shutterstock.com



ISSUES IN DERMATOLOGY

Treating Otitis Externa in Dogs

Patrick Hensel, Dr.med.vet., DACVD, DECVD

Nao Hensel, DVM, MRCVS, DACVD, DECVD

Tierdermatologie Basel, Münchenstein, Switzerland

Canine otitis externa is a common dermatologic problem in small animal practice. Affected ears are often painful and pruritic (e.g., head shaking, scratching); if the condition becomes chronic, it is more difficult to control. Therefore, the primary causes of the ear problem must be identified, eliminated, or managed long term.

Otitis externa is considered a multifactorial disorder; the most common primary cause is allergy, which is often secondarily accompanied by microbial infections (*Malassezia* and bacteria). Other predisposing and perpetuating factors also contribute to the disease process (TABLE 1).^{1,2}

The diagnostic workup for otitis externa requires a detailed history, thorough physical and ear examinations, and cytologic evaluation. Bacterial and fungal cultures are rarely needed unless systemic antimicrobial therapy is necessary for otitis media. Diagnostic imaging (e.g., computed tomography scan, radiography) may be helpful for assessing the extent of mineralization of cartilage in the external ear canal or bone destruction in the middle ear, as well as soft

tissue defects, and determining whether surgical intervention is needed. Radiographic findings may be falsely negative, but radiographs may also be a cost-effective option in general practice. Otoscopy will enable identification of the amount and consistency of ear wax or discharge, any foreign bodies and/or masses, and degree of inflammation and stenosis. Whenever possible, the tympanic membrane should be evaluated for any changes (e.g., opacity) or perforations. Ear cytology, with Diff-Quik staining, is an effective and quick in-house option to confirm and quantify any type of infection and degree of inflammation and should be performed for all dogs with otitis externa.

Most otitis externa cases can be sufficiently managed by topical therapy; however, otitis is likely to return after topical treatment if the underlying cause (e.g., allergy) is not addressed. Before beginning therapy, ensure that the amount of debris in the ear canal is minimal; excessive ear debris should be removed by a deep ear flush. If the ear canals are severely inflamed, the authors recommend pretreatment with

LEND ME YOUR EARS

Ear cytology is a quick way to confirm infection and the degree of inflammation for patients with suspected otitis externa.



systemic anti-inflammatory drugs (e.g., prednisolone) before flushing. A thorough ear flush will enable visualization of the tympanic membrane but will also prevent trapping and inactivation of ear medication in the debris. After successful treatment of an ear infection and inflammation, regular ear cleaning at home (every 7 to 14 days as needed) will also help reduce accumulation of otic material and recurrence of infections. Ear cleaners have different properties (e.g., drying, antiseptic, and/or cerumenolytic) and should be selected according to specific needs. **TABLE 2** lists some of the ear cleaners available on the market.

TYPE OF OTITIS EXTERNA AND TREATMENTS

Acute

Acute otitis externa typically appears as acute onset of increased head shaking/scratching and inflammation for several days. Some cases can be quite painful, and the ear canal can be edematous from the inflammation, which can make an otoscopic examination very difficult, even with the patient under sedation.

The otoscopic examination can be facilitated by giving patients a short course of oral glucocorticoids (e.g., 1 mg/kg prednisone/prednisolone q24h) to help reduce pain and inflammation. A common cause for acute otitis externa is foreign bodies (e.g., grass awns). Removing the foreign body will result in a fast recovery and eliminate the need for further treatment in the absence of secondary infection.

Chronic

Ear diseases that have been present for at least 1 month or that recur frequently are considered chronic. Management of chronic cases is more challenging (**BOX 1**). If the underlying primary cause is not addressed appropriately, antimicrobial drug resistance and/or progressive, nonreversible pathologic changes (e.g., ear canal cartilage mineralization) can result. For up to 70% of dogs with chronic otitis externa, the driving factor for the chronic inflammation is allergy.¹ Given increased moisture, increased temperature, and altered cerumen composition, chronic inflammation within the ear canal provides the ideal environment for microbial overgrowth and infections.

TABLE 1 Causes and Factors Associated with Otitis Externa in Dogs

PRIMARY CAUSES (INDUCE OTITIS IN HEALTHY EAR)	
Allergic dermatitis	Atopy, food adverse reaction, contact hypersensitivity
Foreign bodies	Grass awns, hair, dirt, clumped ear medication, ceruminoliths
Ectoparasites	Otoacariasis, demodicosis, trombiculiasis
Medication reaction	Topical irritants: alcohol, low pH, propylene glycol
Endocrinopathies	Hypothyroidism, Cushing's disease
Hyperplastic disease	Inflammatory polyps
Ear canal neoplasia	Ceruminous gland adenoma/carcinoma, squamous cell carcinoma
Keratinization disorder	Primary idiopathic seborrhea, sebaceous adenitis, vitamin A-responsive dermatosis, zinc-responsive dermatosis
Autoimmune disease	Pemphigus foliaceus, bullous pemphigoid, lupus erythematosus
Immune-mediated disease	Vasculitis, drug reactions, erythema multiforme
SECONDARY FACTORS (CAUSE DISEASE ONLY IN ABNORMAL EAR OR COMBINED WITH PREDISPOSING FACTORS)	
Infections	Most commonly <i>Malassezia pachydermatis</i> , <i>Pseudomonas</i> , <i>Staphylococcus</i>
PREDISPOSING FACTORS (INCREASE RISK FOR OTITIS)	
Conformation	Pendulous ear pinna, stenosis, excessive hair in ear canal
Excessive moisture	Grooming
Overcleaning	Excessive moisture, physical trauma (Q-tips)
PERPETUATING FACTORS (RESULT FROM EAR INFLAMMATION)	
Otitis media	Infectious
Ear canal stenosis	
Ear canal cartilage mineralization	

Although it is important to treat the infections, it is also important to address the inflammation and underlying problem. Depending on the severity of the inflammation and stenosis, oral glucocorticoids may be needed to reduce ear canal inflammation. Prednisolone (1 to 2 mg/kg q12h to q24h for 1 to 3 weeks) or dexamethasone (for more severe cases) is recommended. A pilot study of 5 dogs indicated that cyclosporine may be another potent anti-inflammatory drug and that it may effectively control chronic otitis, especially with long-term use.³ All of these drugs should be used at the lowest possible doses and frequencies to prevent recurrence of the otitis.⁴

Many commercially available topical ear medications contain a combination of antibiotics, antifungals, and glucocorticoids and are supplied in different formulations for daily or weekly applications (TABLE 3). Nevertheless, the authors' clinical observation that many infected ears in atopic dogs contain *Malassezia* raises the question whether commercially available ear medications containing both antibiotics and antifungals should be used for patients with *Malassezia* otitis without bacterial infection. Considering frequent multidrug-resistant bacteria in today's practice, limiting the use of antibiotics is wise.

Malassezia

Malassezia yeast organisms are often secondarily present in patients with chronic ear disease. *Malassezia* otitis typically results in variable degrees of inflammation and excessive, malodorous, mostly brown to dark-brown,

BOX 1 Key Points for the Successful Management of Chronic Otitis Externa

1. Identify and correct primary causes.
2. Remove debris and discharge.
3. Treat secondary infections topically.
4. Treat inflammation topically and orally, as needed.
5. Individualize long-term management.
6. Improve client compliance by providing thorough and clear instructions.
7. Schedule follow-up ear examinations, as needed.

waxy discharge. Of note, however, the number of *Malassezia* organisms seen during cytologic examination does not always correlate with the severity of clinical signs. *Malassezia* organisms not only have the ability to increase hyperplasia and secretion by proteins and enzymes they produce but also may be able to trigger an immune response, resulting in severe inflammation and potentially hypersensitive reaction.⁵ The diagnostic test of choice to confirm *Malassezia* infection is cytology. Fungal culture is not recommended because *Malassezia* organisms are usually not resistant to antimicrobials such as azoles, the organism does not grow well on regular fungal culture media, and standardized susceptibility testing is not available.⁵

TABLE 2 Ear Cleaners and Properties

INDICATION	VETERINARY PRODUCT (MANUFACTURER)
Drying	<ul style="list-style-type: none"> ■ Ear Rinse (PetArmor) ■ Epiotic Advanced (Virbac) ■ EpiKlean (Dechra) ■ MalAcetic Otic (Dechra) ■ Nolvasan Otic (Zoetis) ■ Oti-Clens (Zoetis) ■ Otic-Clean (Pet MD) ■ OtiRinse (Elanco) ■ Zymox Otic (Pet King Brands)
Antiseptic	<ul style="list-style-type: none"> ■ MalAcetic (Dechra) ■ Otodine (ICF) ■ Tris-NAC (ICF) ■ TrizUltra+Keto Flush (Dechra) ■ UltraOtic Rinse (VetBiotek) ■ Vetericyn Plus Ear Rinse (Innovacyn)
Cerumenolytic	<ul style="list-style-type: none"> ■ Cerumene (Vetoquinol) ■ Douxo Micellar Solution (Ceva) ■ KlearOtic (Dechra) ■ pH•notix (Vetoquinol) ■ Zymox Otic (Pet King Brands)

**TABLE 3** Commonly Available Commercial Ear Medications

PRODUCT (MANUFACTURER)	ANTIBACTERIAL	ANTIFUNGAL	GLUCOCORTICOID
Aurizon (Vetoquinol)	Marbofloxacin	Clotrimazole	Dexamethasone
Baytril Otic (Elanco)	Enrofloxacin	Silver sulfadiazine	None
Claro (Elanco)	Florfenicol	Terbinafine	Mometasone
Easotic (Virbac)	Gentamicin	Miconazole	Hydrocortisone
Mometamax (Merck)	Gentamicin	Clotrimazole	Mometasone
Osrnia (Dechra)	Florfenicol	Terbinafine	Betamethasone
Otomax (Merck)	Gentamicin	Clotrimazole	Betamethasone
Posatex (Merck)	Orbifloxacin	Posaconazole	Mometasone
Surolan (Elanco)	Polymyxin B	Miconazole	Prednisolone
Tresaderm (Boehringer Ingelheim)	Neomycin	Thiabendazole	Dexamethasone
TrizUltra+Keto (Dechra)	Tris-EDTA	Ketoconazole	None

Uncomplicated *Malassezia* overgrowth can usually be controlled by regular at-home ear cleaning (e.g., Epiotic Advanced [Virbac, virbac.com]). For more severe and chronic cases, the authors prefer to use a topical product containing antifungal medication (e.g., TrizUltra+Keto Flush [Dechra, dechra.com]). Initially, the ear flush is performed daily until the yeast infection is under control (1 to 3 weeks), followed by once weekly for maintenance. If significant concurrent inflammation is present, dexamethasone SP can be added to TrizUltra+Keto Flush for a final dexamethasone concentration in the range of 0.1% to 0.25%. A recent preliminary in vitro study showed that the dexamethasone SP added to several commercially available ear flush products is stable for 21 to 90 days at room temperature.⁶ Note, however, that *Malassezia* otitis will relapse after the treatment is stopped unless underlying causes are addressed.

Bacterial

The normal microflora within the ear canals is characterized by a diverse population of bacteria in phyla such as Proteobacteria, Actinobacteria, Firmicutes, Bacteroidetes, and Fusobacteria. In patients with chronic otitis externa, the microbial populations become much less diverse and are dominated by organisms such as *Staphylococcus* and *Pseudomonas*, and to a lesser degree by *Corynebacterium*, *Proteus*, *Lactobacillus*, *Streptococcus*, *Porphyromonas*, and *Enterococcus*.⁷ Most bacterial ear infections, especially *Pseudomonas* infections, are characterized by purulent discharge and severe inflammation, some with ulcerations and pain (**FIGURE 1**).

As with *Malassezia*, bacterial ear infections are considered secondary problems; if bacterial infections are recurring, the patient should be thoroughly investigated for primary underlying diseases, such as allergies. The most effective diagnostic tool for identifying (cocci and/or rod shape) and quantitatively assessing bacteria is cytology. Because bacterial otitis externa is treated topically, bacterial culture and

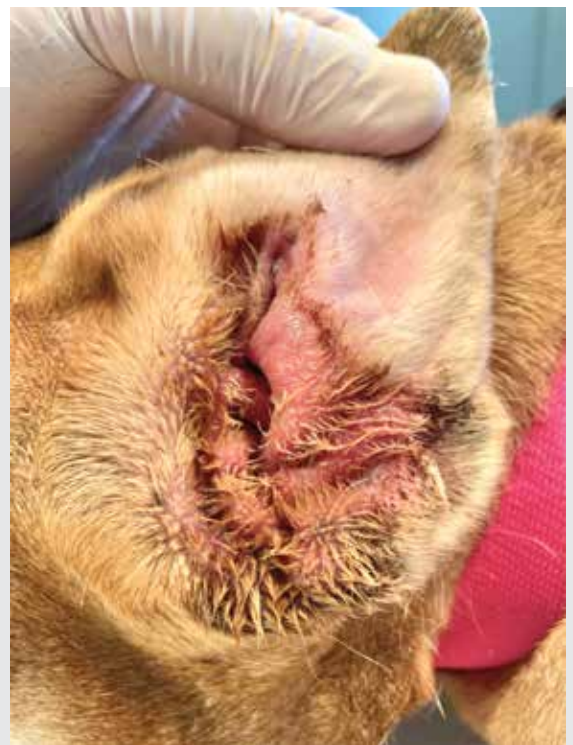

FIGURE 1. Suppurative otitis with erythema and purulent discharge in an atopic dog with secondary *Pseudomonas* otitis.

sensitivity is often not necessary because susceptibility testing cannot accurately determine resistance for topically applied antimicrobials. Minimum inhibitory concentration (MIC) is the lowest concentration of antibiotic that prevents bacterial growth and helps guide susceptibility testing; however, correctly applied topical antibiotics usually reach MICs of up to 100- to 1000-fold. Despite the high MICs, before treatment is started, any debris and purulent discharge must be removed and sufficient ear medication must be applied. The recommended amount is 0.5 to 1 mL (10 to 20 drops) per ear, depending on the size of the patient, and the recommended frequency is 1 to 2 times per day.

To increase client compliance with treatment, 1-mL syringes can be sent home with clients so that they can draw up the recommended amount of ear medication. Numerous commercially available ear products contain antibiotics or disinfectants with antibacterial activity (TABLE 3). Common antibiotics are aminoglycosides (gentamicin, neomycin), fluoroquinolones (ciprofloxacin, enrofloxacin, marbofloxacin, orbifloxacin), polymyxins (colistin sulfate, polymyxin B), fusidic acid, florfenicol, and silver sulfadiazine.⁸

Many chronic cases of bacterial otitis externa are associated with *Pseudomonas* organisms; typically effective antibiotics are fluoroquinolones, gentamicin, and polymyxin B. However, treatment can be complicated by development of multidrug resistance as well as the formation of biofilm.⁹ To enhance the effectiveness of antibiotics, chelating agents such as

Tris-EDTA can be added. These agents weaken the bacterial cell wall and facilitate penetration of the antibiotic into the bacteria. This action has been demonstrated in vitro for multidrug-resistant *Pseudomonas*.¹⁰ Tris-EDTA should be instilled into the affected ear 15 to 30 minutes before application of the topical antibiotic ear medication. It is well tolerated and not ototoxic.

Biofilm

Biofilm has been recognized as a major virulence factor in chronic infections. It increases antimicrobial resistance by shielding bacteria from the immune system and topical medication. Biofilm is an extracellular matrix (i.e., slime) produced by bacteria, which contains extracellular polymeric substances such as extracellular polysaccharides, structural proteins, cell debris, and nucleic acids. Biofilm plays a major role, especially in *Pseudomonas* infections (FIGURES 2 AND 3). It can be found in up to 40% of *Pseudomonas* isolates and increases the antimicrobial MIC needed to treat the infection.⁹

Removing biofilm can be challenging; it needs to be broken down physically by thorough flushing and aspiration. In addition, combination of Tris-EDTA and N-acetylcysteine topical product can help to disrupt and liquify the biofilm.

Parasitic

Various parasites (e.g., *Otodectes*, *Sarcoptes*, *Notoedres*, and harvest mites; ticks) can affect the external ear

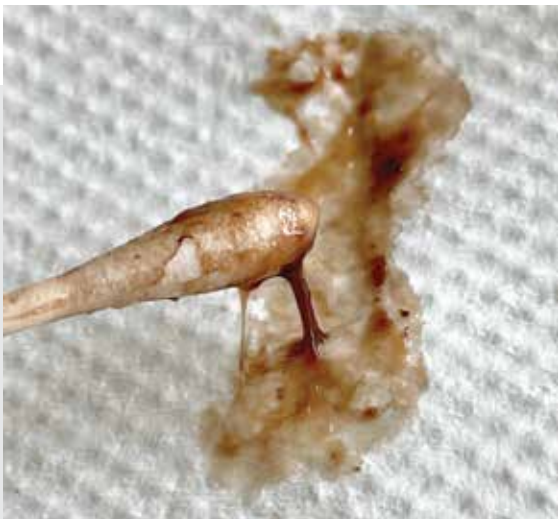

FIGURE 2. Dark, slimy otic discharge from a dog with *Pseudomonas* otitis and biofilm.

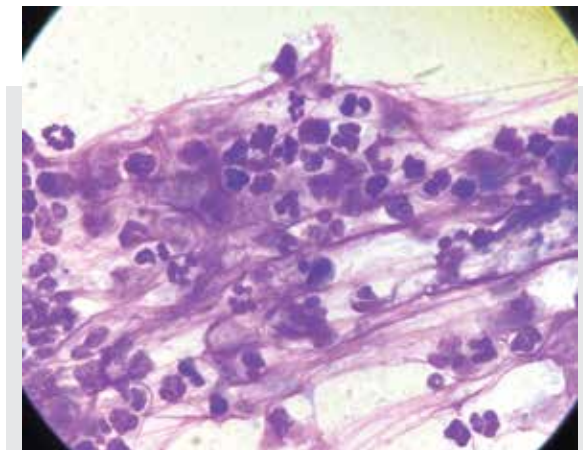


FIGURE 3. Neutrophils and bacteria surrounded by thick purple staining filaments and lace-like material in otic discharge from dog with *Pseudomonas* otitis and biofilm.



canal. *Otodectes cynotis* mites are seen in up to 50% of cats and 5% to 10% of dogs with otitis.¹¹ Even in small numbers, ear mites may cause irritation in the ear canal because of a hypersensitivity reaction. In higher numbers, mites are typically associated with dark-brown, granular (coffee-ground) exudate. Chronic ceruminous otitis externa is sometimes caused by *Demodex* mites.

A few topical acaricidal ear preparations containing ivermectin (e.g., Acarexx Otic Suspension [Boehringer Ingelheim, bi-vetmedica.com]) or pyrethrins are available. However, because many mites and ticks commonly affect other body areas, pesticides with a more systemic or generalized effect are recommended, such as spot-on topicals (e.g., selamectin, fipronil, moxidectin) or oral isoxazoline (e.g., fluralaner, soralaner).

SURGICAL INTERVENTIONS

Although treating otitis externa can be challenging, most chronic and recurrent cases can be medically treated and successfully managed, especially when underlying causes are addressed. Under certain circumstances, a surgical intervention may be necessary, but it should be performed only after all primary causes have been identified and corrected. Indications for surgery are tumors/polyps, end-stage otitis with severe

mineralization, or unsuccessful medical treatment. Because of the severity of chronic otitis and potential involvement of the middle ear, the most effective surgical procedure is total ear canal ablation combined with lateral bulla osteotomy; however, clients must be informed about the potential risks and postsurgical complications.

CLIENT EDUCATION

It is very important to clearly and thoroughly discuss with clients the requirements for successfully managing chronic otitis. Discussions should address the primary causes (e.g., allergies), determine what the client is able to do at home (ear cleaning and treatment), determine how cooperative the patient is, and ensure that the client understands the instructions and is willing to return for follow-up visits every 2 to 4 weeks. To increase client compliance, show them how to clean and treat the ears, provide detailed written instructions, and schedule follow-up calls, all of which can be done by skilled veterinary nurses. To increase patient compliance, provide pain control and ensure that ear cleaning and treatment are gently performed. **TVP**

References

1. Paterson S, Matyskiewicz W. A study to evaluate the primary causes associated with *Pseudomonas* otitis in 60 dogs. *J Small Anim Pract.* 2018;59(4):238-242.
2. Saridomichelakis MN, Farmaki R, Leontides LS, et al. Aetiology of canine otitis externa: a retrospective study of 100 cases. *Vet Dermatol.* 2007;18(5):341-347.
3. Hall JA, Waisglass SE, Mathews KA, Tait JL. Oral cyclosporine in the treatment of end-stage ear disease: a pilot study. *Vet Dermatol.* 2003;14:212.
4. Nuttall T. Successful management of otitis externa. *In Practice.* 2016;38:17-21.
5. Chen T, Hill PB. The biology of *Malassezia* organisms and their ability to induce immune responses and skin disease. *Vet Dermatol.* 2005;16(1):4-26.
6. Emery CB, Outerbridge CA, Knych KH, et al. Preliminary study of the stability of dexamethasone when added to commercial veterinary ear cleaners over a 90-day period. *Vet Dermatol.* 2021;32(2):168-e39. doi: 10.1111/vde.12924
7. Borriello G, Paradiso R, Catozzi C, et al. Cerumen microbial community shifts between healthy and otitis affected dogs. *PLoS ONE.* 2020;15(11):e0241447. doi: 10.1371/journal.pone.0241447
8. Koch SN, Torres SM, Plumb DC, editors. Section 2: Otic preparations. In: *Canine and Feline Dermatology Drug Handbook*. Ames, IA: Wiley-Blackwell; 2012:369-393.
9. Pye C, Yu A, Weese JS. Evaluation of biofilm production by *Pseudomonas aeruginosa* from canine ears and the impact of biofilm on antimicrobial susceptibility in vitro. *Vet Dermatol.* 2013;24:446-449.
10. Buckley L, McEwan N, Nuttall T. Tris-EDTA significantly enhances antibiotic efficacy against multidrug-resistant *Pseudomonas aeruginosa* in vitro. *Vet Dermatol.* 2013;24(5):519-e122.
11. Glaze MB. Chapter 19: Diseases of eyelids, claws, anal sacs and ears. In: Miller WH, Griffin CE, Campbell KL, editors. *Muller & Kirk's Small Animal Dermatology*. 7th ed. St. Louis, MO: Elsevier; 2013:724-773.

Nao Hensel

Dr. Nao Hensel obtained her doctor of veterinary medicine degree from Colorado State University in 2010. She then completed a 1-year rotating small animal internship in Massachusetts followed by a 3-year veterinary dermatology residency in Georgia. A native of Japan, Dr. Hensel subsequently moved to Basel, Switzerland, where she opened a veterinary dermatology practice in 2014.



Patrick Hensel

Dr. Patrick Hensel is a 1996 graduate of the University of Bern, Switzerland. After completing a doctorate thesis and a rotating internship at the University of Zurich, Switzerland, he moved to the United States, where he completed a 3-year veterinary dermatology residency at the University of Georgia in 2004. He stayed on as a faculty member until 2013, when he decided to move back to Switzerland to open his own dermatology clinic in his hometown of Basel in 2014.

